



Texas School for the Blind & Visually Impaired  
Outreach Programs

512-454-8631 | [www.tsbvi.edu](http://www.tsbvi.edu) | 1100 W. 45th St. | Austin, TX 78756

# **Selected Anomalies and Diseases of the Eye**

**Compiled by  
Virginia E. Bishop, Ph.D.**

**Reprinted with permission by  
Texas School for the Blind & Visually Impaired**

**1986**

# Introduction

This collection of eye diseases and anomalies was prepared for the Teacher of the Visually Impaired, who may need a rapid reference for consultative and interpretive purposes.

Most of the conditions will be found in school age or preschool children and youth. A few exceptions were included, since they occur commonly in the visually impaired population (e.g., diabetic retinopathy, presbyopia).

Every effort has been made to be accurate, concise and objective, however, it is recognized that there may be a variety of opinions among educators and eye specialists (particularly concerning treatment implications). Each visually impaired individual is unique, and should be viewed as such; treatments and educational considerations must be designed to meet individual needs.

This Manual should not be considered a complete information guide. There is no substitute for a detailed ophthalmological textbook, and every Teacher of the Visually Impaired should own at least one. A reference list is included at the end.

Since medical technology and knowledge is constantly being expanded, several blank pages have been included in the back of this Manual. The user is encouraged to add notes or references as needed.

It is hoped that this Manual will serve the needs of Teachers of the Visually Impaired as it was intended. These persons are often the facilitators of success for visually impaired children and youth, and have historically been liaison agents between educators and the eye care professions. Perhaps this Manual will enhance those functions.

V.E.B

Note: Texas School for the Blind & Visually Impaired was given permission to post this document on our website. This is such a valuable publication. We are grateful to Virginia Bishop for sharing it.

# Table of Contents

Albinism .....	1
Amblyopia .....	2
Aniridia .....	3
Aphakia.....	4
Astigmatism .....	45
Blepharitis .....	5
Buphthalmos.....	6
Cataract .....	7
CHARGE Association.....	49
Chorioretinitis .....	8
Coloboma .....	9
Color deficiency.....	10
Corneal scarring .....	11
Cortical blindness .....	12
Diabetic retinopathy .....	13
Dislocated lens .....	14
Enucleation .....	15
Esophoria, Esotropia .....	44
Exophoria, Exotropia .....	44
Glaucoma .....	16
Hemianopsia .....	17
Histoplasmosis .....	18
Hordeolum.....	19
Hyperopia .....	45
Hyperphoria, Hypertropia .....	44
Hyporphoria, Hypotropia .....	44
Keratitis .....	20
Keratoconus.....	21
Macular degeneration .....	22
Microphthalmus.....	23
Muscle imbalances.....	44
Myopia .....	45
Nystagmus .....	24
Optic atrophy .....	25
Papillitis.....	27
Photophobia.....	28
Presbyopia .....	45
Ptoxis .....	29
R.L.F./R.O.P.....	35
Refractive errors.....	45

**Retinal degeneration ..... 30**  
**Retinal detachment ..... 31**  
**Retinitis Pigmentosa ..... 32**  
**Retinoblastoma..... 33**  
**Retinoschisis ..... 34**  
**Rubella..... 36**  
**Scotoma ..... 37**  
**Strabismus ..... 44**  
**Sympathetic ophthalmia ..... 38**  
**Syndromes ..... 47**  
**Toxoplasmosis ..... 39**  
**Trachoma ..... 40**  
**Tumors ..... 41**  
**Uveitis ..... 42**  
**Wounds ..... 43**  
**References ..... 53**  
**Additional Resources..... 54**

# Albinism

---

## Description:

A hereditary deficiency of pigmentation, which may involve the entire body (complete albinism) or a part of the body (incomplete albinism); believed to be caused by an enzyme deficiency involving the metabolism of melanin during prenatal development; inherited as an autosomal dominant or recessive trait; in the X-linked type, ocular albinism is only visible ophthalmologically in the female carrier; in complete albinism, there is usually lack of pigmentation in skin and hair, as well as in retinal & iris tissue; in incomplete albinism, skin and hair may vary from pale to normal; in ocular albinism, function may vary from normal to impaired. Impairments may involve the retina (especially the macula) and iris; photophobia, nystagmus, and refractive errors are typical. If acuity is decreased, it commonly ranges between 20/70 and 20/200. Visual fields are variable; color vision is usually normal. Prognosis: non-progressive.

---

## Treatment:

Optical correction of refractive errors; tinted or pinhole contact lenses; absorptive lenses; optical aids; lowered illumination if needed; genetic counseling recommended.

---

## Implications:

Adjust illumination to conditions and individual (i.e., control glare via seating and/or tinted lenses; use sunglasses and/or hat with visor outdoors). Classroom seating should be appropriate to the corrected refractive error and photophobia. Should be evaluated for low vision aids. Genetic implications should be noted.

# Amblyopia

---

## Description:

(also known as "amblyopia ex anopsia," which is dimness of vision from disuse). In the absence of organic eye disease, reduced visual acuity in one eye (uncorrectable with lenses) due to cortical suppression; commonly caused by strabismus or by unequal refractive errors, but may also be caused by opacities of the lens or cornea. In strabismus, the image from the deviating eye is suppressed; fusion is lost, as is depth perception. If treatment is not instituted early, vision fails to develop in the deviating eye, and cannot be regained. In older children (over about 8 years of age), amblyopia may be untreatable. (see also Strabismus)

---

## Treatment:

Optical correction of refractive errors; occlusion ("patching") and/or orthoptics (eye exercises); surgery to straighten eyes. (Peak age for strabismus surgery success is age 2. Chances for improvement of acuity decrease until approximately age 8, after which acuity improvement is unlikely.)

---

## Implications:

Early detection and treatment is essential if acuity is to be developed and maintained. Lighting according to individual needs. If amblyopia is untreatable (as in an older child), classroom seating should favor the functional eye.

# Aniridia

---

## Description:

Rare, congenital absence or partial absence of the iris; genetically caused by an autosomal dominant or recessive hereditary pattern. Often, the iris is vestigial (little more than a margin is present) and the eye appears to have no color (only a larger than normal pupil). Other deformities of the anterior chamber are also often present (e.g., cataract), and glaucoma frequently develops before adolescence. There is usually decreased acuity (circa 20/200), photophobia, possible nystagmus, cataracts, displaced lens, and underdeveloped retina; visual fields are usually normal, unless glaucoma develops.

---

## Treatment:

Pinhole contact lenses; tinted lenses and/or sunglasses; corrections for refractive errors; optical aids; lower illumination levels to control glare. If glaucoma develops (and regular monitoring for this is essential), medical and/or surgical treatment (i.e., goniotomy or trabeculotomy) may help, but long-term prognosis is poor.

---

## Implications:

Control glare through lenses or illumination level. Magnification may be helpful. Genetic counseling is indicated.

# Aphakia

---

## Description:

Absence of the lens, due to surgical removal, perforating wound or ulcer, or congenital anomaly; causes a loss of accommodation, hyperopia, and a deep anterior chamber. Complications include detachment of the vitreous or retina, and glaucoma.

---

## Treatment:

Strong convex lens prescription, in glasses or possibly contact lenses.

---

## Implications:

Good illumination, but avoid glare and excessive light; seating away from windows; good contrast in printed materials.

There is currently some controversy over the use of "black light" with aphakic children. Ultra-violet light is thought to be absorbed by the lens, thus protecting the retina from exposure. When there is no lens to perform this function, the retina is exposed and may be damaged. Precautionary measures suggest that the use of "black light" with *any* child should be limited, and that care should be taken to shield the light source from the eyes (i.e., do not allow the child to look directly into the light source).



# Blepharitis

---

## Description:

A common, chronic, bilateral inflammation of the lid margins; may be staphylococcal (ulcerative) or seborrheic (non-ulcerative), or a combination of the two; may run a chronic course over a period of months or years if not treated adequately. The seborrheic type is associated with dandruff. Symptoms are itching, burning, irritation, and scaly appearance of the lid margins. Conjunctivitis, mild keratitis, chalazions and hordeola may be complications.

---

## Treatment:

Scalp, eyebrows, and lid margins must be kept clean and scales removed daily. Antibiotics or sulfonamide ointments are possible medications.

---

## Implications:

Good personal hygiene and immediate/adequate medical care are essential for the prevention and treatment.

# Buphthalmos

---

## Description:

Infantile glaucoma, caused by abnormal development of the angle formed by cornea and iris; Schlemm's Canal is usually collapsed; onset at birth or before age 3 (over 80% of cases are evident by 3 months of age); usually an autosomal recessive trait. Symptoms are excessive tearing, photophobia, increased intraocular pressure, and cupping of the optic disk. The eyes usually appear abnormally large; corneal haze is not uncommon. In untreated cases, blindness occurs early. The earlier the defect appears, the less favorable the prognosis. Long-term visual prognosis is fair. Depending on when treatment is instituted, there may be lowered acuity or restricted visual fields. Must be treated surgically (goniotomy, trabeculotomy, or trabeculectomy).

---

## Treatment:

Surgical treatment, at the earliest possible time, is essential if vision is to be saved.

---

## Implications:

If visual fields are restricted, Orientation and Mobility instruction is indicated.

# Cataract

---

## Description:

A clouding or opacity of the lens, believed to be caused by chemical changes in the lenticular structure/material. Etiology includes: hereditary, congenital anomalies associated with disease or syndrome; infection, severe malnutrition, or drugs during pregnancy; systemic disease (e.g., diabetes); trauma (e.g., head injury or puncture wound); normal manifestation of old age. May be congenital, senile, or traumatic. Symptoms include whitish appearance of the pupil and blurred vision/decreased acuity (especially at distance). The congenital type may also include nystagmus, squint, photophobia; traumatic cataract symptoms include general redness and irritation of the eye, and may be complicated by infection, uveitis, retinal detachment, and glaucoma.

---

## Treatment:

There is no medical treatment -- only surgical. Congenital cataracts (not caused by rubella) should be removed within the first few months of life if acuity is to develop normally; contact lenses or glasses provide the accommodative power of the missing lens. (Depending on the type of surgery, secondary cataracts sometimes reappear, and repeat surgery is necessary.) Senile cataract removal is followed by one or more of the following: cataract glasses, contact lenses, or intraocular lens implant. Complications of cataract surgery include vitreous and/or retinal detachments and glaucoma.

---

## Implications:

Variable lighting to reduce glare in persons with unoperated cataracts. Lighting should be from behind to reduce glare.

Note: Children with cataracts caused by maternal rubella usually do not have surgery until at least age 2, since the live virus is present in ocular tissues many months after birth. Such children have less favorable prognoses for good acuity following surgery, since the period for retinal stimulation has passed.

Genetic counseling may be indicated.

Educational note: A child with a central, unoperated cataract may have some unusual head positions; these should be tolerated, since the child is essentially "looking around the cataract."

Magnification is helpful in some cases

# Chorioretinitis

---

## Description:

A type of posterior uveitis, almost always affecting the retina; usually follows an active microbial invasion of the tissues by a causative organism which is rarely recovered (definite etiological diagnosis is seldom possible); generally classified as granulomatous. The onset may be *in utero* when caused by the *Toxoplasma gondii*, probably the most common cause (see Toxoplasmosis) . If granulomatous uveitis is *acquired*, the onset is insidious: vision gradually becomes blurred, pain is minimal, mild photophobia is present, and the pupil is often constricted and/or irregular in shape. Fresh lesions seen through the ophthalmoscope appear as yellowish-white patches through a hazy vitreous. As healing occurs, the vitreous clears and pigmentation appears at the edges of the lesions. In the healed stage, there is considerable pigmentation (i.e., "scars") and scotomas occur where the lesions are located; these healed areas usually do not result in significant visual loss. If the macula has not been involved, recovery of central vision is complete. The disease can last months to years, sometimes with remissions and exacerbations, and is capable of causing permanent damage with marked visual loss.

---

## Treatment:

Must be treated medically, usually with anti-infective agents and systemic corticosteroids. Although organisms responsible for toxoplasmosis and tuberculosis (both possible causes of chorioretinitis) may be activated by corticosteroids, they are given as a calculated risk to control the inflammatory response when vision is threatened.

---

## Implications:

Functional vision depends on the extent and site(s) of the healed lesions. If the macular area was not involved, central acuity remains normal and the scotomas are usually not significant in terms of visual functioning. However, if the macula was involved, the lowered acuity can result in markedly reduced visual functioning. Magnification may be helpful.

# Coloboma

---

## Description:

Congenital cleft in some part of the eye (commonly the iris, but may also occur in the lid(s) or pigment epithelium and choroid); caused by faulty closure during prenatal development; usually hereditary; secondary complication: cataracts. Associated conditions are: microphthalmia, polydactyly and mental retardation. Depending on the extent and location of the coloboma, there may be decreased visual acuity, nystagmus, strabismus, photophobia, and a loss of visual fields.

---

## Treatment:

Cosmetic contact lenses and/or sunglasses for colobomas of the iris. Optical aids may be helpful.

---

## Implications:

Visual fields measurement is suggested when a coloboma of some part of the inner eye is suspected (i.e., choroid or pigment epithelium).

# Color deficiency

---

## Description:

A defect of the cones which affects color detection; called "achromatopsia" in its most extreme form; X-linked genetic defect occurring in 8% of men and 0.4% of women; may also be *acquired* as a result of retinal disease (specifically when it affects the macula) or poisoning. Type depends on which cones are affected:

Cone Monochromats have only one type of cone and may be red-green, red-blue, or green-blue blind; occurs one in a million.

Dichromats have two types of cones; this group is further divided into: Protanopes (red-blind; see blue and green), Deuteranopes (green- blind; confuse shades of red, green and yellow), and Tritanopes (blue- blind; see red and green).

Anomalous Trichromats make up the largest group and are similar to the Dichromatic group except in intensity (Protans and Protanopes, Deutrans and Deuteranopes, Tritans and Tritanopes ... similar but milder defects.

Rod Monochromatism is very rare; there is complete lack of cone function and accompanying photophobia, nystagmus, and poor visual acuity; visual fields are normal. The photophobia and nystagmus reduce with age.

---

## Treatment:

(There is no treatment for color deficiencies; in the case of achromatopsia, optical aids, sunglasses, and lowered illumination may be helpful.)

---

## Implications:

Although color blindness is more of a social inconvenience than a handicap, educators should be aware of students with this condition since many educational materials utilize color as an instructional vehicle. Students with color blindness may need to learn compensatory techniques for sorting or selecting clothing or interpreting traffic signals.

Genetic counseling may be indicated.

# Corneal scarring

---

## **Description:**

May be caused by injury to the cornea (abrasion, laceration, burns, or disease); depending on the degree of scarring, vision can range from a blur to total blindness. Surface abrasions, although extremely painful, heal transparently (do not leave scars). Deeper abrasions and ulcerations/lacerations result in a loss of corneal tissue, which is replaced by scar tissue. Scars left from burns depend on the type and depth of burn: boiling water or a curling iron leave superficial scarring; acids or alkalies cause deeper damage unless neutralized immediately. Scarring from disease (usually an inflammation) is usually the result of a proliferation of new blood vessels into the clear cornea, to assist in the healing process. Diseases which cause vascularization include herpes simplex, syphilis, and keratitis.

---

## **Treatment:**

When corneal scarring is dense enough to affect vision, a corneal transplant is indicated. This procedure is 90% successful because of the minimal rejection rate (due to a lack of blood supply in the cornea).

---

## **Implications:**

The best treatment is prevention (of disease and injury). Educational needs will vary, according to individual conditions (extent and location of corneal scar tissue in relation to the pupil) The level of illumination and print size may be factors to consider also.

# Cortical blindness

---

## Description:

A term used to describe an apparent lack of visual functioning, in spite of anatomically and structurally intact eyes. The cause is assumed to be a lack of cortical functioning (i.e., the visual cortex of the brain is non-functional). Children with "cortical blindness" do not exhibit nystagmus, however. (Nystagmus may be the way the nervous system responds to bad vision, since it occurs simultaneously with many visual impairments.) Neither a CAT scan nor a VEP can confirm cortical function. In the absence of other abnormalities (e.g., optic atrophy, microcephaly, frequent seizing), the prognosis is good for regaining some degree of visual functioning in children with "cortical blindness."

---

## Treatment:

Vision stimulation activities of all kinds are appropriate, over a long period of time. However, the potential for improved visual functioning is probably better in the younger child than in the adult. Fibers of the optic tract and their connections (the extrageniculostriate system) may be important in visual recovery, since they are theorized to be 1) important in the maintenance of a stationary optical image on the retina via reflex eye movements; 2) essential for the provision of visual feedback for cerebellar coordination of learned skilled movements; and 3) mediators in visual functioning with the geniculostriate system.

---

## Implications:

It is currently believed\* that the pliability of the young brain may be a factor in this positive prognosis. The recovery pattern is not easily detected by standard ophthalmic tests, since visual behaviors are unique and somewhat unusual (e.g., many children recover the ability to identify single letters of large print when well isolated; most recover the ability to name colors; most can detect moving targets in the peripheral field better than in the central field). Short term evaluations should not determine visual potential, since progress may take time. Dramatic and significant visual recovery can happen over a long term (a decade or more).

---

\* This information taken from a presentation by Creig Hoyt, M.D. (a pediatric ophthalmologist) at the 10th International Seminar on Preschool Blind Children, October 7-10, 1984, Asilomar, California.



# Diabetic retinopathy

---

## Description:

The adult-onset form of diabetes is a metabolic disease which ultimately affects retinal blood vessels, causing intraretinal hemorrhaging and abnormal growth of new vessels into the vitreous; the vitreous then pulls away from the retina, and the vessels hemorrhage into the vitreous. This bleeding blocks the transmission of light through a normally transparent vitreous, and functional visual interference results (ranging from "floaters" to blindness). Symptoms of ocular involvement include: sensitivity to glare, diplopia, lack of accommodation, fluctuating acuity, diminishing of color vision, and lessening of visual fields; retinal detachment may follow; secondary complications include glaucoma and cataracts. Other associated systemic conditions include cardiovascular, skin, and kidney problems. If diabetes is well controlled in its early years, the onset of retinopathy is delayed, and its severity is reduced; ocular complications occur about 20 years after the onset, even when it is well controlled. Once retinopathy is established, it is little affected by the day-to-day control of diabetes. High blood pressure should be vigorously treated. In juvenile diabetes, severe retinopathy develops within 20 years in 60%-70% of the cases, even when the diabetes is well controlled. Cataracts are rare in juvenile diabetes, but form rapidly (within several weeks) if they occur. Senile cataracts are common in older diabetics.

---

## Treatment:

Control of the diabetes is essential (through diet, exercise, urine testing, and insulin therapy if needed), as is the control of high blood pressure. Photocoagulation may help when vision is affected by a focal area of retinal edema, and may delay the onset of proliferative retinopathy. It may also be used to alleviate drastic complications later, although not necessarily preserving macular function (central acuity) . Trans-pars plana vitrectomy helps about 75% of patients who have sustained visual loss due to hemorrhaging. Retinal detachment may be treated with scleral buckling, photocoagulation, and vitrectomy

---

## Implications:

Low vision aids and increased illumination may be helpful when visual function is maintained.

Diabetic retinopathy is one of the leading causes of visual impairment. It is the most common cause of blindness in younger people throughout the world, although the visual outlook for the adult onset type is better than for the juvenile type. In a random population of diabetics, a little over one third will have some type of diabetic retinopathy, however less than 5% will develop the severest symptoms; 1% of these will become blind.

# Dislocated lens

---

## Description:

Lens dislocation may be partial or complete, and may be hereditary or result from trauma. If hereditary, it is usually bilateral and associated with other disorders (e.g., aniridia, Marfan's syndrome). It may be complicated by cataract formation. Vision is blurred if the lens is dislocated out of the line of vision. If dislocation is partial and the lens is clear, visual prognosis is good. Traumatic lens dislocation can follow a blow to the eye. If the dislocation is partial, the eye may be asymptomatic, but if the lens has become totally detached and is floating in the vitreous, there is blurred vision. A quivering iris may be a symptom of lens dislocation, due to the lack of lens attachment and support. Iritis and glaucoma are common complications.

---

## Treatment:

Dislocated lenses are best left untreated when there are no complications.

If a dislocated lens becomes opaque, surgical removal should be delayed as long as possible because vitreous loss and subsequent retinal detachment are common complications of such surgery. If uncontrollable glaucoma occurs, lens extraction is necessary, in spite of the risks involved.

Reading lenses and/or aphakic lenses may be needed.

---

## Implications:

(see also description for Aniridia) The child with a dislocated lens may need extra time for tasks requiring clear vision, and may exhibit unusual head positions as he exerts extra energy to see.

# Enucleation

---

## Description:

The surgical removal of the eyeball from its orbit. Indications for removal include:

1. When trauma is so extensive that the form of the eyeball cannot be preserved;
2. Prevention or treatment of sympathetic ophthalmitis;
3. Severe pain in a blind eye;
4. Iridocyclitis, phthisis bulbi, and glaucoma when accompanied by severe pain or inflammatory symptoms;
5. Malignant tumors;
6. Anterior staphyloma, if the eye is blind, troublesome and disfiguring;
7. Early panophthalmitis;
8. Intra-ocular foreign bodies which cannot be removed and which cause irritation;
9. Cosmetic improvement in blind and disfigured eyes;
10. Unilateral retinoblastoma

---

## Treatment:

Artificial eyes are worn after enucleation, for cosmetic purposes and to fill the cavity left between the eyelids. In addition, a prosthesis prevents the eye lashes from turning in and irritating the conjunctiva. A prosthesis can be worn as soon as the socket is free from inflammation (about 1 month). It is usually made of plastic material, which is more expensive than glass, but is unbreakable and needs replacement less often. A prosthesis should be cleaned often.

---

## Implications:

If only one eye has been removed (and the other eye has normal visual function), the only impairment in visual abilities will be lack of depth perception. A protective lens for the good eye may be indicated; Orientation & Mobility instruction may also be needed, to orient to the loss of the 90 degree periphery

If both eyes have been removed (or if the remaining eye is impaired), adaptive measures will be needed. These could include training in communication skills and daily living skills, Orientation and Mobility instruction, and vocational guidance. Since extreme changes in visual functioning involve elements of emotional reactions, psychological counseling may also be indicated.

# Glaucoma

---

## Description:

A condition of the eye characterized by intraocular pressure (i.e., the production of aqueous fluid by the ciliary body exceeds the drainage rate through the trabecular system and Canal of Schlemm). Classification includes three basic types: primary glaucoma (both open-angle or simple glaucoma, the most common type, and closed-angle or acute/chronic type), congenital glaucoma (buphthalmos or hydrophthalmos and juvenile types associated with congenital anomalies), and secondary glaucoma (due to changes in the lens or uveal tract, trauma, rubeosis, surgical procedures, or topical corticosteroids). Heredity seems to predispose individuals to glaucoma, although it may also be related to medications and/or surgical procedures in other parts of the eye. If untreated, the effects can cause damage to the optic disk, restricted visual fields, and corneal edema; cataracts also often develop. Complete blindness can result. When treated early, the condition can be successfully managed medically. Because its onset is so gradual, all adults should be checked regularly for glaucoma.

---

## Treatment:

Glaucoma cannot be "cured" -- only controlled. Miotics help to facilitate aqueous drainage, and other medications (also in eyedrop form) decrease aqueous production. When these measures do not halt the advancing damage to visual fields or optic nerve, surgery (to clear or enlarge the drainage system) is indicated; it is a procedure of last resort. Trabeculectomy and trabeculotomy are microsurgical techniques with high success rates.

Educational note: There may be periods of fluctuating vision if medication level also fluctuates. Fatigue may be a factor in regulating assignments.

---

## Implications:

There is some evidence to suggest that stress tends to exacerbate glaucoma; therefore, emotional upset should be avoided. Excessive fatigue should also be avoided. Optical aids and illumination control (e.g., sunglasses) are recommended as needed, since photophobia and decreased visual acuity are symptoms of glaucoma. A unique characteristic of this disorder is the observation by the patient of halos around lights \* Early identification and ongoing control are essential if visual function is to be maintained. Genetic counseling may be indicated.

---

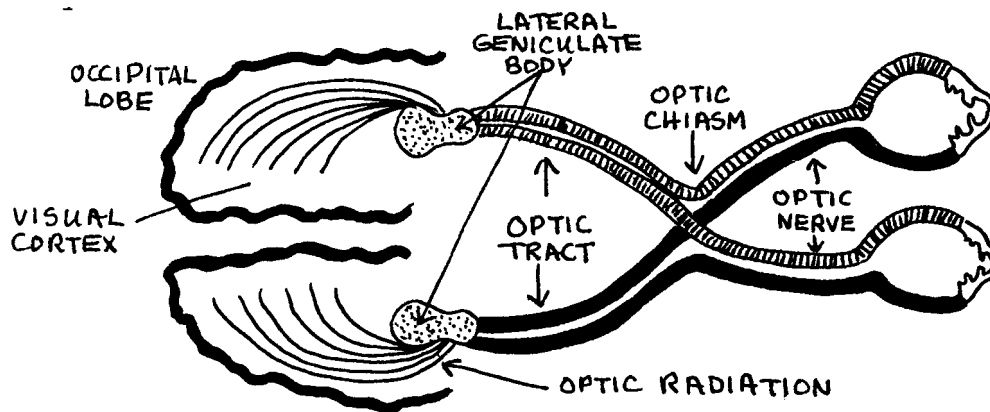
\* Halos around lights may also be a sign of incipient cataracts.

# Hemianopsia

---

## Description:

Literally, "half vision;" a condition resulting from malfunction or damage to one side of the optic tract (see diagram below). Images from only one half of each eye reach the brain; thus, there is only reception of half-fields for each eye.



---

## Treatment:

There is no treatment for hemianopia itself; the *cause* (e.g., tumor or hemorrhage) should be investigated and treated if possible. Visual fields losses can sometimes be alleviated with prism lenses, but their efficient use depends on the individual user (motivation, perceptual ability, etc.). Orientation and Mobility adjustments may be indicated. Reading may be affected, depending on whether the loss is in the right (in reading, the "anticipatory" field) or left fields.

---

## Implications:

Examination of the diagram will suggest that different types of visual losses occur when sites of malfunction differ (e.g., a tumor affecting the optic chiasm will cause visual impairment in both eyes, but a tumor affecting either optic nerve will affect only one eye).

# Histoplasmosis

---

## **Description:**

Disease of the choroid; caused by an invasion of a fungal organism; transmitted by airborne spores found in dried animal excrement; the peripheral fundus has "punched-out" spots similar to healed chorioretinal lesions, but smaller and less pigmented. Macular involvement may occur later (believed to be a result of earlier choroidal sensitization and subsequent reinfection); these macular lesions may progress to hemorrhagic detachments. There is no vitreous haze. There is a positive reaction to a skin test for the disease. It seems to occur more often in the eastern half of the United States.

---

## **Treatment:**

Many treatments have been advocated, including systemic corticosteroids, antihistamines, and photocoagulation of perimacular leakage, but results have been questionable in all cases. Once disciform changes begin, prognosis is very poor.

---

## **Implications:**

In the initial stages, when only the peripheral fundus is affected, the vision is not affected (except for peripheral scotomas, which do not usually interfere with visual functioning). If the macula becomes involved, decreased central acuity, deficient color vision, and central scotoma can cause considerable loss of visual function. Optical aids may be helpful in these cases.

# Hordeolum

---

## Description:

A common staphylococcal infection of the lid glands; essentially an abscess, with pus formation; symptoms include swelling, redness, and pain. Two types are classified: internal hordeolum (relatively large, affecting the meibomian glands; may point toward the skin or toward the conjunctiva) and external hordeolum (also known as a "sty;" smaller and more superficial; an infection of the glands of Moll or Zeiss; painful; always points toward the skin side of the lid margin).

---

## Treatment:

Both types of hordeola are treated with warm compresses for 10-15 minutes 3-4 times a day; if the condition does not improve within 48 hours, incision and drainage of the pus is indicated. Antibacterial ophthalmic ointment is also helpful.

---

## Implications:

Although hordeola are not visually threatening, they are uncomfortable and should be treated; prevention of infection spreading to other parts of the eye is a consideration. A large internal hordeolum has the potential to affect the entire lid through accompanying cellulitis. Personal hygiene, especially for children, is an indication

# Keratitis

---

## Description:

A term used to define a wide variety of corneal infections, irritations, and inflammations; since each type of condition is unique, medical diagnosis and treatment is essential. Corneal ulcers are commonly caused by bacterial or fungal invasions following superficial corneal abrasions; among the common infectious agents are: staphylococcus, streptococcus, herpes (both simplex and zoster), adenovirus, rubeola, rubella, mumps, trachoma, infectious mononucleosis, and pneumococcus; also at fault may be Vitamin A deficiency or broad spectrum antibiotic drug reactions. Corneal ulcers may also follow trauma, may be associated with other eye infections (e.g., conjunctivitis), may be related to other corneal disorders (e.g., degenerative conditions, or ptosis, which may cause a "dry eye"), or may arise from a variety of systemic disorders (especially those of autoimmune origin). Symptoms of corneal infection include extreme pain and photophobia.

---

## Treatment:

Medical treatment is absolutely essential -- even a delay of a few hours can affect the ultimate visual result. The causative factors must be determined through laboratory analysis of scrapings; medical treatment (i.e., medication) varies according to the cause.

---

## Implications:

It is extremely important to treat keratitis before corneal tissue is destroyed and scar tissue is formed. Because the pain is so severe in keratitis, the patient usually welcomes medical attention. However, if the cornea loses its sensitivity (as in trauma, surgery, or damage to the trigeminal nerve), ulcers can develop without accompanying pain. The implications for personal hygiene are evident, especially with children. Handwashing during periods of illness and following toileting is of vital importance as a preventive measure.



# Keratoconus

---

## Description:

A rare, bilateral, degenerative disease; inherited as an autosomal trait; affects all races; appears in the second decade of life, and progresses slowly between the ages of 20 and 60; associated with a number of other diseases, including Down's syndrome, atopic dermatitis, retinitis pigmentosa, aniridia, Marfan's syndrome. Keratoconus is literally an increasing conical shape to the cornea; the central cornea thins and may rupture in advanced stages. Blurred vision is the only symptom, however, examination shows a distorted corneal reflection and an inability to see the fundi.

---

## Treatment:

Contact lenses improve visual acuity in the earliest stages. A corneal transplant is indicated when the corrected visual acuity decreases beyond the patient's tolerance for functional activities.

---

## Implications:

If a corneal transplant is done before corneal thinning occurs, about 80%-95% of patients retain reading vision. Genetic counseling may be indicated.

# Macular degeneration

---

## Description:

Hereditary and untreatable group of diseases which affect the macular area of the retina. When the disease affects the choriocappilaris, as in central areolar choroidal sclerosis, there is gradual loss of central vision in middle life. Genetically, this type of macular degeneration is autosomal dominant or recessive. Other types of macular degeneration affect the pigment epithelium. Stargardt-Behr disease is transmitted genetically as an autosomal recessive factor; it results in gradual deterioration of the pigment epithelium, which begins at different ages and progresses at different rates; rate and degree of visual loss varies from family to family. In Best's vitelliform macular degeneration (an autosomal dominant genetic pattern), changes are confined to the macula. Initially, it resembles a poached egg "sunny side up;" later, the "yolk" appears scrambled, and central vision is seriously decreased. (see also Scotomas)

---

## Treatment:

Untreatable

---

## Implications:

Identification of the type of deterioration may be helpful in educational planning, however, the wide range of resulting visual loss and rate of degeneration makes prediction of final visual status impossible. Regular fundus examination may indicate changes which will have implications for educational and/or rehabilitative planning. Genetic counseling is indicated.

Eccentric viewing may be observed in an attempt to utilize peripheral input.

# Microphthalmus

---

## **Description:**

Abnormal smallness of one or both eyes; congenital, and almost always hereditary (usually recessive, but may also be dominant) . Other ocular abnormalities also occur, including cataract, glaucoma, aniridia, and coloboma. Systemic and anatomic abnormalities also often occur; these include: polydactyly, syndactyly, clubfoot, polycystic kidneys, cystic liver, cleft palate, and meningoencephalocele. Deficient vision is the rule.

---

## **Treatment:**

Lens correction for refractive errors, often tinted; lighting according to needs, to control glare.

---

## **Implications:**

Genetic counseling is indicated

# Nystagmus

---

## Description:

Involuntary, rhythmical, repeated oscillations of one or both eyes, in any or all fields of gaze; may be pendular (with undulating movements of equal speed, amplitude, and duration, in each direction) or jerky (with slower movements in one direction, followed by a faster return to the original position). Movements may be horizontal, vertical, oblique, rotary, circular, or any combination of these. Generally, the faster the rate, the smaller the amplitude (and vice versa). The defect is classified according to the position of the eyes when it occurs. Grade I occurs only when the eyes are directed toward the fast component; grade II occurs when the eyes are also in their primary position; grade III occurs even when the eyes are directed toward the slow component. The cause of nystagmus is unknown. Reduced acuity is caused by the inability to maintain steady fixation. Head-tilting may decrease the nystagmus and is usually involuntary (toward the fast component in jerky nystagmus, or in such a position to minimize pendular nystagmus). Head nodding often accompanies congenital nystagmus. Dizziness or vertigo may be experienced if oscillopsia (illusory movements of objects) occurs. Nystagmus may be induced with an optokinetic drum or through the stimulation of the semicircular canals. Congenital nystagmus of the pendular type usually accompanies congenital visual impairment (e.g., corneal opacity, cataract, albinism, aniridia, optic atrophy, chorioretinitis). Nystagmus may also accompany a number of neurological disorders, and may be a reaction to certain drugs (including barbiturates).

---

## Treatment:

There is no known treatment, however, certain types of jerky nystagmus (commonly Grade I types) show spontaneous improvement in childhood (up to age 10). This type may also be amenable to muscle surgery (essentially, a repositioning of muscles to take advantage of the point of least nystagmus, or position of relative rest).

---

## Implications:

With the exception of brief experiences of oscillopsia, most individuals with nystagmus perceive objects as being stationary. It is believed that the brain is responsible for the perceptual adjustment.

Educationally, children with nystagmus (who may tend to lose their place in beginning reading instruction) may be helped through the use of a typoscope (card with a rectangular hole, to view one word or line at a time) or an underliner (card or strip of paper to "underline" the line being read) . As children with nystagmus mature, they seem to need these support devices less often.

# Optic atrophy

---

## Description:

Dysfunction of the optic nerve; may be congenital or aquired. If congenital, it is usually hereditary. The milder form is autosomal dominant and has a gradual onset of deterioration in childhood but little progression thereafter; the more severe form is autosomal recessive and is present at birth or within 2 years; this form is accompanied by nystagmus. Leber's Disease has an unclear mode of inheritance but is suspected of being X-linked, since it only rarely occurs in women; optic neuropathy occurs more commonly in 20-30 year old males; some vision is retained but there are varying degrees of impairment. The acquired type of optic atrophy may be due to vascular disturbances (occlusions of the central retinal vein or artery or arteriosclerotic changes within the optic nerve itself), may be secondary to degenerative retinal disease (e.g., papilledema or optic neuritis), may be a result of pressure against the optic nerve, or may be related to metabolic diseases (e.g., diabetes), trauma, glaucoma, or toxicity (to alcohol, tobacco, or other poisons). Loss of vision is the only symptom. Pale optic disk and loss of pupillary reaction are usually proportionate to the visual loss.

---

## Treatment:

There is no known treatment, since degeneration of optic nerve fibers is irreversible. Since changes in visual function occur gradually (over weeks or months), ophthalmoscopic observations are not reliable predictors of functioning until disk cupping and marked pallor are noted; these are unfavorable signs. Visual loss as a result of pressure against the optic nerve may be restored if the cause is identified and treated early. Optic atrophy secondary to vascular, traumatic, degenerative, and some toxic causes has a negative prognosis.

---

## Implications:

Enhancing visual function may require high levels of illumination and enlarged print with high contrast; magnification may be useful in some cases. Color perception may be impaired.

Since it is impossible to identify exactly which fibers of the optic nerve are involved, it should not be assumed that the optic nerve is not functioning at all; a better assumption might be that the visual stimulus is experiencing difficulty in *getting* to the brain; if and when it arrives, it may be in distorted or incomplete form. Thus, perceptual function may be greatly affected. Moreover, day-to-day classroom performance of a student with optic atrophy may fluctuate with no apparent reason. The child may not be aware of these fluctuations; the classroom teacher should be alerted to their possibility.

Note:

Optic nerve hypoplasia should not be confused with optic atrophy. Optic nerve hypoplasia is an *undeveloped* optic nerve due to a neurological insult early in the prenatal developmental period; the optic nerve has started to develop, but regresses. Ophthalmologically, the nerve head appears unusually small, and is surrounded by a white "halo" of scleral tissue showing through.

The anomaly appears to be related to chronic alcohol and drug abuse by the mother during the prenatal period. CAT scans of these children reveal defects in the septum pellucidum and posterior corpus callosum; those who lack the septum pellucidum have spatial orientation problems. At least one third of these children had low APGAR scores and end up to have endocrine problems. Most have some type of neurological problems. Visual acuity ranges from normal to severely impaired.

# Papillitis

---

## Description:

(also known as optic neuritis) A general term implying inflammation of the optic nerve, but also includes degeneration or demyelination of the optic nerve; included retrobulbar neuritis, a condition affecting the optic nerve *behind* the optic disk (i.e., there are no visible changes of the optic nerve head unless optic atrophy has occurred). Causes include demyelinating diseases (e.g., multiple sclerosis, postinfectious encephalomyelitis), systemic infections (viral: polio, flu, mumps, measles; bacterial: pneumonia et al), nutritional and metabolic diseases (diabetes, pernicious anemia, hyperthyroidism), Leber's Disease, secondary complications of inflammatory diseases (e.g., sinusitis, meningitis, tuberculosis, syphilis, chorioretinitis, orbital inflammation), toxic reactions (to tobacco, methanol, quinine, arsenic, salicylates, lead), and trauma. Papillitis is differentiated from papilledema; it is unilateral instead of bilateral, shows less elevation of the nerve head, and sluggish pupillary response. In optic neuritis, there is usually a severe but temporary loss of vision for several days and pain in the eye when moved.

---

## Treatment:

Treatment is directed toward the underlying cause. Systemic corticosteroids may be helpful, but the tendency *without* treatment is toward improvement. Visual acuity usually begins to improve in 2-3 weeks, and sometimes returns to normal in a few days.

---

## Implications:

Central scotomas are the most common visual field defect, but any unilateral field change is possible. A single attack of optic neuritis is not likely to leave severe damage, but permanent and significant visual loss is probable over a period of years when recurrent attacks are experienced.

# Photophobia

---

## Description:

A condition of abnormal sensitivity to light (i.e., the amount of light entering the eye); usually, the iris is unable to constrict enough to reduce the light entering the eye. This condition is normally a symptom of associated disorders or disease (e.g., corneal inflammation, aphakia, iritis, or ocular albinism) Some drugs and/or poisons also can cause photophobia by causing pupil dilation (notably, amphetamines and antihistamines, cannabis and cocaine, atropine, scopolamine, mydriotics and cycloplegics [See Implications] and strychnine).

---

## Treatment:

Treatment should address the *cause*, since photophobia is a *symptom*. Photogray lenses, sunglasses and/or sun visors are adaptive measures. In school children with ocular conditions for which photophobia is an accompanying symptom (notably albinism, aniridia, aphakia, dislocated lens, but possibly also cataracts and/or glaucoma), controlled illumination and preferential seating are suggested. Light sources should be shielded to prevent direct light into the eyes, and attention should be given to eliminating glare from paper, texts, desk tops and blackboards.

---

## Implications:

A number of drugs are used to dilate the pupils during an eye examination. Mydriatics only dilate the pupils; cycloplegics dilate the pupils *and* paralyze the muscles used in accommodation. Photophobia is a temporary condition following the use of these drugs.

Multiply handicapped children who are on a program of supervised medication may exhibit dilated pupils. These children should always be suspected of being photophobic, whether their behavior suggests it or not.



# Ptosis

---

## Description:

A drooping of the upper eyelid when the eyes are open; may occur in one or both eyes; may be constant or intermittent. If the condition is congenital, it is usually a failure of the levator muscle to develop; it may be hereditary (dominant). If the condition is acquired, it is usually the result of a mechanical factor (the lid is simply too heavy for the levator muscle to lift it), associated with disease (commonly muscular dystrophy or myasthenia gravis), or paralytic (related to the malfunctioning of the 3rd cranial nerve). If the lid droops enough to partially cover the pupil, the person attempts to compensate by raising the eyebrow and/or by tilting the head back. If the drooping lid obscures the pupil completely, amblyopia can develop. Disease-caused ptosis progresses gradually; neurally associated ptosis has a range of developmental patterns and behaviors, depending on the type of cranial nerve involvement.

---

## Treatment:

If the condition does not interfere with visual functioning and does not look cosmetically deforming, it is best left untreated. Surgical correction is possible when vision is threatened.

---

## Implications:

Following ptosis surgery, occasionally the eye will not fully close at night. To prevent the eye from drying, ophthalmic ointment or drops may be prescribed.

# Retinal degeneration

---

## **Description:**

Retinal tissue may degenerate for a number of reasons. Among them are: artery or vein occlusion, diabetic retinopathy, R.L.F./R.O.P. or disease (usually hereditary). Retinitis pigmentosa, retinoschisis, latic degeneration, and macular degeneration are characterized by progressive types of retinal degeneration. (see also Macular Degeneration and Retinitis Pigmentosa)

---

## **Treatment:**

Varies, according to cause, symptoms, or effects. Adaptations in the learning environment may include a variety of optical aids and controlled illumination (especially for glare). Genetic counseling may be indicated.

---

## **Implications:**

Schoolchildren with diagnoses of retinal degeneration disorders should be under regular and routine ophthalmological care, since retinal detachments are possible.

# Retinal detachment

---

## Description:

The retina is only firmly attached at the optic nerve head and at the ora serrata; elsewhere, the vitreous and general structure of the eye hold the retina in place. If, through disease, trauma, or a puncture wound, the retina is thinned or tears, vitreous fluid can leak behind the retina and cause it to pull away from its normal position. If the peripheral retina pulls away it can usually be reattached with little loss of visual function. If, however, the macular area is pulled away and is separated from its capillary nourishing connections, severe visual impairment (even total blindness) can result. Among the predisposing conditions for retinal detachment are: high myopia, aphakia, vitreous abnormalities (including diabetic retinopathy), retinal degeneration, and trauma. Symptoms may range from none, to "flashing lights" and/or "floaters," to loss of visual function. Immediate medical attention is essential.

---

## Treatment:

Treatment consists of bonding the retina to the choroid through diathermy (high frequency current which sears the choroid and retina), cryotherapy (freeze-bonding), or photocoagulation (laser burning). All three procedures induce scar tissue (essentially, "spot welding"). Scleral buckling (literally, a "buckle" around the outer sclera, which, when tightened, forces the choroid to make a contact with the retina) may assist with the bonding procedure. Educational adjustments include increased illumination and optical aids.

---

## Implications:

Prognosis depends on the cause of the detachment. Any eye report for a school child which indicates a detached retina in one eye should raise questions about contact sports and strenuous activity.

# Retinitis Pigmentosa

---

## Description:

A group of diseases which result in the degeneration of the retina; cause is unknown, but suspected to be an enzyme in the retina; most types are hereditary, but the pattern of inheritance varies. Rods are destroyed, beginning in the mid-periphery, and gradually advancing inward toward the macula; "tunnel vision" is retained in the most common types, but central acuity is also diminished in other types; many are myopic. Many develop cataracts but are not as likely to have glaucoma or detached retinas. In Usher's syndrome (5% prevalence among R.P.), central acuity is retained but there is accompanying hearing loss; this type emerges during the teen years. In the "centro-peripheral" type of R.P. (17% of cases), onset is around 6-15 years of age, there is no nystagmus, and both central and peripheral vision are affected. In Leber's Disease (26% of R.P. cases), both central and peripheral vision are affected, nystagmus is present, and cataracts do *not* usually develop; it is congenital. The most common type (52%) also appears during the teen years, is typified by severe and progressive peripheral loss, but good central acuity (no worse than 20/50) is maintained until around age 60. Varieties of the common type are genetically different, and have characteristic loss of central acuity at different ages (e.g., 40-60). A few syndromes have R.P. as a component (e.g., Laurence-Moon-Biedl). Night blindness is the initial symptom and occurs early; deterioration of peripheral vision follows.

---

## Treatment:

There is no known treatment for R.P. There is considerable research effort in this direction. Monitoring of retinal degeneration (locus and rate of change) via ERG and ophthalmoscopy of widest retinal periphery. A variety of optical aids may be effective (e.g., magnifiers if fields are not severely restricted, hand telescopes, CCTV, and "pocketscopes" -- infra-red devices for night use). Prism lenses may be useful. Higher levels of illumination may be helpful.

---

## Implications:

Genetic counseling is essential. Functional vision evaluations may need to be "as needed" (rather than annually). Identification of the type of R.P. is essential in establishing prognosis. Retinal specialists are usually better qualified to examine the widest area of the retina viewable. Regular eye exams are desirable, to track the rate and degree of deterioration.

# Retinoblastoma:

---

## Description:

A malignant and life-threatening intraocular tumor which appears in children; 2/3rds appear before age 3, however, rare cases have been reported at almost every age. About 30% are bilateral. It usually is unnoticed until it has progressed to a point of producing a white pupil (unless it has caused a strabismus and is diagnosed earlier, since blind eyes in children will often turn inward). Generally, the earlier the tumor is discovered, the better the chance to treat it and prevent its spread through the optic nerve and orbital tissues. About 94% of these tumors are due to mutations, but survivors will pass the mutated gene on about 50% of the time.

---

## Treatment:

Enucleation is the treatment of choice when the tumor is large; radiotherapy and/or chemotherapy are other possibilities. Occasionally, cryotherapy or photocoagulation are effective. When retinoblastoma is bilateral, enucleation is done on the worst eye first, with radiotherapy attempted on the other eye. If no improvement is observed, enucleation is done on the second eye. Genetic counseling is essential.

---

## Implications:

Since enucleation is an immediate and necessary treatment of retinoblastoma, these children will be blind early in life. Although educational programming will involve tactile and auditory techniques, there will often be good spatial orientation because of the early presence of some degree of vision. (Congenitally totally blind children do not have the benefit of this early spatial orientation.) There is some evidence that children with retinoblastoma have better tactile discrimination than other totally blind children, and many of them are above average in intelligence.

# Retinoschisis

---

## Description:

A term meaning a splitting of the retina into two layers; the separation is due to peripheral cystoid degeneration. The juvenile type occurs before 10 years of age, and macular involvement is frequent. The senile type occurs from age 20 on, commonly after age 40, and there is usually no significant visual loss. If no retinal holes develop, there are rarely serious consequences. If the retina does tear, and subsequently detaches, it may be treated with photocoagulation, cryotherapy, diathermy, or scleral buckling. If the detachment threatens the retina, it *must* be treated if vision is to be retained. Retinoschisis appears to be an X-linked trait

---

## Treatment:

Routine and regular retinal examination is suggested, so that changes in the retina may be monitored. Unless the macula is involved, no educational adjustments are indicated. Genetic counseling may be indicated.

---

## Implications:

Limiting of contact sports may be desirable.

# **R.L.F./R.O.P.**

**(Originally called retrolental fibroplasia;  
now called retinopathy of prematurity.)**

---

## **Description:**

One of the most devastating, baffling, and controversial ocular conditions involving young children; first reported in the 1940's and theorized to be caused by excess oxygen administered to premature infants; current theories suggest that the cause may not yet be known, since it has also begun to occur in full-term infants who did not receive oxygen. Among the causative theories are: too much light, too soon, in hospital neonatal units; Vitamin E deficiency; multiple factors associated with prematurity. Ocular involvement follows a pattern of initially constricted ocular blood vessels, followed by vascular dilation and fibrovascular proliferation into the vitreous (thus, the term "retrolental fibroplasia" -- literally, fibrous retinal vessel tissue behind the lens). In some cases, there is partial or complete regression of the condition, with little ocular damage. In other cases, the retina is pulled away and blindness ensues. Occasionally, the condition is unilateral. Myopia and strabismus are common among children who retain useful vision, and there is a possibility of retinal detachment in later life. Glaucoma, uveitis, cataract, or phthisis bulbi (shrunken blind eye) may also occur months or years later.

---

## **Treatment:**

Careful monitoring of retinal status in premature infants; if vessel development appears abnormal, removal of oxygen support usually allows spontaneous regression of the condition. (If there are respiratory or other problems requiring the use of oxygen for the survival of the infant, it may be impossible to control the deterioration of the ocular condition). Other complicating eye conditions should be monitored.

Educational adaptations include a variety of optical aids (hand magnifiers, hand telescopes, CCTV). Myopic corrections are usually indicated, as well as high level of illumination. If visual acuity is too low to use magnification effectively, adaptations will change accordingly.

---

## **Implications:**

There is some evidence, though inconclusive, that children with RLF/ROP have a higher than normal incidence of social and/or emotional problems (particularly autistic-like behaviors). Research has not yet established a definite link, but it is thought that some as yet undefined factor associated with prematurity may be responsible.

# Rubella

---

## Description:

Maternal rubella (German measles) in the first trimester of pregnancy is generally responsible for a triad of defects in the fetus: heart defects, hearing problems and eye problems; mental retardation also often accompanies these defects. Ocular involvement is typically cataracts (bilateral in 75% of the cases) but also may include uveal colobomas, searching nystagmus, microphthalmus, strabismus, retinopathy, and infantile glaucoma.

---

## Treatment:

Cataract surgery is usually delayed until at least age 2, since the live rubella virus remains in ocular tissues for many months after birth. Unfortunately, this preferred delay also results in a poor prognosis for visual functioning following cataract removal. Monitoring of ocular status (for complications) is recommended.

Educational adjustments will vary, according to functional vision. Optical aids and/or illumination levels should be according to individual needs. Glare may be a factor.

---

## Implications:

Some physicians are recommending therapeutic abortion in cases of maternal rubella, since the probability of serious congenital anomalies is so high.



# Scotoma

---

## Description:

Portion(s) of the retinal field that are non-functional (i.e., blind areas). Scotomas may be central, if caused by macular or optic nerve disease, or peripheral if the result of chorioretinal lesions or retinal holes. Field testing, if carefully done, can identify the areas affected.

---

## Treatment:

There is no treatment for scotomas. When they are in the peripheral areas and are not large, they usually do not cause severe problems in general visual functioning. If the scotomas are large or numerous, mobility may be affected.

Central scotomas are another situation entirely. Functional acuity is severely affected and educational adjustments are indicated. Magnification or large print may be indicated. Higher levels of illumination and good contrast in reading materials may also be useful. Color perception may be affected.

---

## Implications:

Eccentric viewing may be a symptomatic and spontaneous adjustment to a central scotoma.

# Sympathetic ophthalmia

---

## Description:

A rare, bilateral granulomatous uveitis, associated with either a perforating eye injury in the region of the ciliary body or a retained foreign body in the eye. The exact cause is unknown, but it is believed to be related to sensitivity (i.e., a reaction) to uveal pigment. It has been known to follow uncomplicated intraocular surgery for cataracts or glaucoma. The injured eye becomes inflamed first, and the other eye follows (i.e., "sympathetically"). Symptoms include photophobia, redness, and blurred vision; in some cases, there are also "floaters" and possibly pain. The history of trauma differentiates this condition from other types of granulomatous uveitis; other differentiating factors include its bilateral, diffuse, and acute nature. (see also Wounds)

---

## Treatment:

A severely injured eye with poor prognosis for visual functioning should be enucleated to prevent sympathetic ophthalmia. If this is done within 10 days following the injury, the chances are almost nil of later sympathetic ophthalmia in the good eye. If, however, inflammation in the sympathizing eye is relatively advanced, enucleation of the injured eye is not recommended; visual function is likely to be severely impaired in both eyes, but the injured eye may turn out to be the better of the two eyes, since optic nerve damage (due to papilledema) and secondary glaucoma may occur in the sympathetic eye.

Local corticosteroids and atropine (and possibly systemic corticosteroids) may be administered immediately if sympathetic inflammation has been diagnosed. Untreated, sympathetic ophthalmia can progress to complete bilateral blindness over a period of months or years

---

## Implications:

If an eye report indicates severe trauma to an eye (notably a puncture wound or a retained foreign object), sympathetic ophthalmia is a threat. Since it may occur 10 days to many years following the injury, the individual should seek medical attention immediately at the first sign of blurred vision, redness, or photophobia.

# Toxoplasmosis

---

## Description:

A type of granulomatous uveitis caused by a protozoan parasite (*Toxoplasma gondii*); rats, birds, or humans can become infected by ingesting the parasite which is found in cat feces; ingestion of raw meat is another source of the disease. There are two types: congenital and acquired. The congenital type is a result of intrauterine infection; the inflammatory process is more severe and is often bilateral; chorioretinitis is almost always present. Cerebral involvement, with radiopaque calcification and mental retardation occurs in about 10% of the congenital types. The acquired type may appear at any age and is usually milder; it is often unilateral and frequently does not involve the central nervous system. The eye may not even be involved in the acute stage, but chorioretinitis may occur in the chronic form. Typically, the chorioretinitis progresses to a healed stage, leaving scars on the retina and choroid. If the macula has been involved, loss of central vision is permanent. The condition is not progressive, but usually chronic; new lesions may develop later. (see also Chorioretinitis)

---

## Treatment:

Treatment is first with anti-infective drugs and then with corticosteroids if the initial treatment is ineffective. Prognosis for cure is fair to poor; visual impairment depends on the location of the healed scars (i.e., macula or periphery). Educational adaptations include the use of magnification.

---

## Implications:

Pregnant women who own cats should refrain from handling the litter during pregnancy, since the fetus could become infected in utero. All cat owners should exercise caution in disposing of cat litter; scrupulous personal cleanliness is essential. Children who have cats as pets should be encouraged to wash their hands often, especially after caring for their cats.

# Trachoma

---

## Description:

A form of bilateral keratoconjunctivitis which causes corneal scarring; at its onset, it resembles conjunctivitis with symptoms of tearing, photophobia, pain, swelling of the eyelids, and superior keratitis; as it passes through four stages, the conjunctival tissues become follicular, heal, and finally scar. Lacrimal glands and ducts are often affected as well; the upper lid may turn inward and the lashes then abrade the cornea; corneal ulceration results, becomes infected, and ultimately scars. When scarring is extensive, blindness results. The disease is spread by contact; flies and gnats may also transmit it.

---

## Treatment:

If treated early (with antibiotics, usually tetracycline drugs or sulfonamides), the prognosis is excellent. Untreated, it can cause blindness.

---

## Implications:

This disease is one the earliest recorded eye diseases; it was identified as early as the 27th century B.C. It is the leading cause of blindness worldwide, and afflicts over 400 million people (primarily in underdeveloped countries in Africa, the Middle East, and Asia). It is preventable with adequate diet, proper sanitation, and education. It is rare in the United States.

# Tumors

---

## Description:

May occur in any part of the eye or its related structures; may be benign or malignant. Lid tumors of the benign type include nevi, warts, molluscom contagiosum, xanthelasma, and hemangioma; malignancies of the lids include carcinoma, sarcoma, and melanoma. The conjunctiva is also a site for a number of both benign and malignant growths. The cornea is subject to extensions of conjunctival carcinomas and melanomas. Intraocular tumors are more difficult to differentiate (between the benign and malignant types) since biopsy is difficult, if not impossible. Orbital tumors are difficult to identify until they are large enough to displace the eyeball. The CAT scan and ultrasonography are often used as diagnostic tools, and help to locate the tumor for surgical exploration. (see also Retinoblastoma)

---

## Treatment:

Treatment varies from local excision to radiotherapy to enucleation, depending on the location, size, and type of growth. Educational considerations should follow recommendations based on a functional vision evaluation.

---

## Implications:

Many tumors can be diagnosed early, since they are usually visible, interfere with vision, or displace the eyeball to some extent. Delay in diagnosis can lead to difficulties in treatment and/or surgery, and possible loss of useful vision. Enucleation may be necessary if the tumor is life-threatening (as in retinoblastoma).

---

## Description:

Broadly defined: an inflammation of the uveal tract (one or all three parts); has many causes, but often the cause is unknown; common mainly among young and middle-age groups. Two types are distinguished: non-granulomatous (which occurs mainly in the iris and ciliary body) and granulomatous (which commonly occurs in the posterior, or choroid/retina area). Non-granulomatous uveitis is the more common type and is typified by acute onset, pain, photophobia, blurred vision, a small and irregular pupil, and a marked circumcorneal flush; there is usually no vitreous haze; it is usually unilateral. Recurrence is common, but the prognosis is good. Granulomatous uveitis is characterized by an insidious onset, minimal or no pain, only slight photophobia, blurred vision, a small and irregular pupil, and often a vitreous haze; prognosis is fair to poor. Uveitis is associated with other diseases (e.g., rheumatoid arthritis, tuberculosis, toxoplasmosis, histoplasmosis, toxocariasis, pars planitis, sympathetic ophthalmia, sarcoidosis). Anterior uveitis may cause glaucoma or cataract, vitreous degeneration, and retinal detachment. Posterior uveitis nearly always involves both choroid and retina (chorioretinitis), leaving scars and scotomas.

---

## Treatment:

Treatment for nongranulomatous uveitis includes warm compresses (10 minutes, 3-4 times a day), systemic analgesics for pain, dark glasses for photophobia, and dilation of the pupil with atropine; local steroid drops are also effective. Systemic steroids may be indicated in severe and unresponsive cases. Granulomatous uveitis is commonly treated with mydriatics and corticosteroids. (see also Chorioretinitis and Toxoplasmosis)

---

## Implications:

Because the types, causes, and treatments vary in uveitis, medical diagnosis and treatment is essential. School children's learning environments may require temporary adjustments or long-term adaptations, depending on the type and extent of the uveitis.

# Wounds

---

## Description:

May be non-penetrating or penetrating; if non-penetrating, can be due to abrasion (usually corneal or conjunctival), contusion, or burns. Although abrasion injuries are painful, they usually heal quickly after treatment. Contusions may result in hemorrhages (a "black eye," subconjunctival bleeding, vitreous and/or retinal hemorrhaging), ruptures (of the cornea, root of the iris or iris sphincter, dislocation of the lens, choroidal rupture and/or retinal detachment), paralysis or spasm of the muscles of accommodation, or optic nerve injury. Secondary complications of contusion may be traumatic cataract or secondary glaucoma. Thermal burns damage eye tissue much as they do other skin tissues, but corneal burns may result in opaque scar tissue. Ultraviolet irradiation (e.g., unfiltered ocular exposure to an electric welding arc) can produce a superficial keratitis (which is painful but usually heals quickly). Solar macular burns cause permanent visual damage; excessive X-ray exposure produces later cataractous changes.

Penetrating injuries include corneal and conjunctival foreign bodies (which usually heal well and produce no visual loss unless the central cornea is involved), lacerations (both of the lids and of the eyeball), and intraocular foreign bodies. The prognosis for lacerations depends on the extent (depth) of the wound, and whether there has been any loss of ocular contents.

Intraocular foreign bodies are the most serious type of penetrating wounds. Identification and localization of the object is essential, since some materials (e.g., glass or porcelain) may be tolerated and left alone, while others (e.g., copper or iron) must be removed because of later chemical reactions within the eye. Moreover, damage to ocular structure and/or tissue must be detected prior to treatment decision.

---

## Treatment:

Treatment varies according to the type and extent of the wound. Most superficial wounds are painful but heal well with treatment. Subconjunctival hemorrhages *appear* worse than they are, and usually self-absorb in time. Internal ocular injury is less visible and always requires examination by a medical eye specialist. **All eye injuries, whether superficial or serious, should be seen and treated by an ophthalmologist.**

---

## Implications:

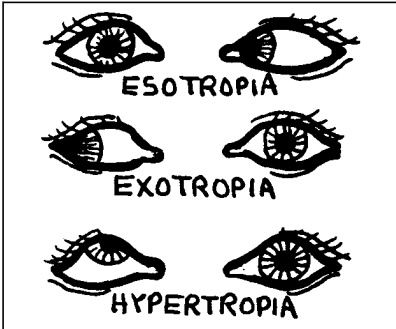
Tetanus inoculation is indicated whenever the eye is penetrated by injury.

# Muscle imbalances

---

## Description:

*Strabismus* is a term used to describe defects of the eye muscle system. It includes "phorias" (tendencies, or *latent* muscle imbalances which are controlled by the brain's efforts toward binocular vision) and "tropias" (observable deviations which the brain cannot resolve). *Esotropia* is the deviation of one eye toward the nose. *Exotropia* is the deviation of one eye toward the temporal side of the face. *Hypertropia* is the deviation of one eye upward. Deviations downward are very rare. Deviations may occur with either eye, alternately (e.g., alternating esotropia or alternating exotropia) or may be monocular (always the same eye). Esotropia is the most common defect, is often present at birth, but may appear as late as 4 years of age if due to accommodation; exotropia is less common in infancy and childhood and is usually intermittent. Hypertropia is the least common, and is often compensated for by head tilting. Strabismus is commonly an inherited defect (autosomal dominant) but may also be caused by paresis or secondary to other body defects.



---

## Treatment:

The goals of correcting strabismus are: good acuity in both eyes, good cosmetic appearance, and binocular vision. Occlusion ("patching") of the good eye forces the deviating eye to develop acuity, and should be initiated as early as possible. It is most effective before age 1, and becomes more difficult by age 5; it is ineffective beyond age 7. Early diagnosis and occlusion are the best first steps in preventing amblyopia. When no further improvement of acuity can be accomplished by patching, surgical realignment of the eye muscles is indicated (occlusion does not straighten the eyes, only improves acuity). Surgery repositions eye muscles through recession (repositioning a muscle to make it "longer") or resection (essentially "shortening" a muscle). Strabismus surgery is rarely precise; more than one operation may be needed to achieve optimal results. Orthoptics (eye exercises) are sometimes prescribed before or after strabismus surgery, to help improve fusion; an amblyoscope may be used to measure fusion as well as to induce it.

---

## Implications:

Since the muscles of the eyes are responsible for coordinated movements and binocular vision, strabismus should be identified and treated as early as possible. The younger a child is, the better the prognosis. Strabismus is never "outgrown" and vision may be permanently lost if strabismus is left untreated. (see Amblyopia)

School vision screening usually happens too late to help most children with strabismus. Preschool vision screening is highly desirable. Alert parents and/or pediatricians can also recognize strabismus and should follow-up with a professional eye examination.



# Refractive errors

---

## Description:

In a normal eye, parallel rays of light focus exactly on the fovea (the central area of the macula), when the eye is in a state of rest (i.e., the lens does not have to accommodate). In a farsighted (*hyperopic*) eye, under the same conditions, the eyeball is too short, and the light rays focus (theoretically) behind the fovea. In a nearsighted (myopic) eye, under the at-rest conditions, the eyeball is too long, and the light rays come to a focus before they reach the fovea.

*Astigmatism* is an irregular curvature of the cornea in one or more of its meridians. The lens may also contribute to astigmatism (as in old age, when it may become somewhat irregular in shape because of cataractous changes). Astigmatism may be simple (i.e., not combined with hyperopia or myopia), or compound; when an eye has both myopia and astigmatism or hyperopia and astigmatism, it is a compound defect. Astigmatism may also be "mixed" (when myopia is combined with hyperopic astigmatism, or when hyperopia is combined with myopic astigmatism). In middle age (beginning anytime past age 40), the lens becomes less flexible and less able to accommodate for nearpoint viewing; this condition is called "presbyopia" and is described as "when arms aren't long enough." In addition to simple myopia or hyperopia and the variations of astigmatism, and because the human organism has *two* eyes which must have coordinated visual reception for good vision to occur, a multitude of refractive variations are possible. *Anisometropia* refers to different refractive errors in each eye, and *aniseikonia* denotes a difference in the image size in the two eyes.

Refractive errors tend to be inherited, but there is no pattern of inheritance. Size of the eyeball, shape of the cornea, shape of the lens, and depth of the anterior chamber are all variables in refractive errors. These variables increase the possible ocular combinations for refractive errors.

Symptoms of myopia include squinting and frowning; hyperopia may cause a lack of interest in reading, rubbing of the eyes, or even headache, dizziness, or nausea. Astigmatism may cause visual fatigue, headaches, frowning, and squinting.

Degenerative myopia (sometimes also called progressive myopia) is similar to simple myopia except that the degenerative changes occur in the optic disk, choroid and retina, sclera, and vitreous, and are not related to the degree of myopia (i.e., the myopia does not increase; the structure of eye parts changes in such a way that visual function is negatively affected). Loss of central vision, retinal detachment, and vitreous opacities are typical; cataracts and secondary glaucoma may be additional complications. Progressive myopia is genetically determined as a recessive trait.

---

## Treatment:

Myopia and hyperopia are treated by the use of spherical concave and convex lenses, respectively. Astigmatic corrections are cylindrical and are added to any prescription for myopia or hyperopia. Presbyopia necessitates the use of bifocals or trifocals. In the absence of disease or other ocular abnormalities, glasses or contact lenses are the only treatment needed for refractive errors.

---

## Implications:

The wearing of glasses does not "strengthen" or weaken" eyes, or affect the degree and progress of myopia. Eye exercises are of no benefit in improving refractive errors, since they cannot alter the size of the eyeball or the refractive power of the lens.

Current interest in radial keratotomy (the surgical changing of the shape of the cornea) suggests possible "cures" for high myopia and astigmatism, but the surgical techniques are still in experimental stages. Long-term effects have yet to be observed, analyzed, and documented.

Contact lenses have revolutionized the corrective lens industry, however, both hard and soft contact lenses continue to be somewhat controversial. As with surgical solutions to refractive errors, there are precautions and problems yet to be solved. Contact lenses are preferable to glasses in some kinds of corneal anomalies and in unilateral aphakia, but their general use still assumes user integrity. Severe ocular injury can occur if contact lenses are used carelessly. Moreover, certain occupations (e.g., beauticians) should avoid the use of the soft lenses, since they tend to absorb chemicals that could be harmful to the eye. The decision to wear contact lenses must be made with care; they are not "for everybody."

About 80% of children are hyperopic at birth because of the shortness of the eye; approximately 5% are myopic. During the years between ages 2 and 25, there is a gradual decrease in hyperopia; myopia usually increases somewhat during the teen years, and levels off at around age 25, regardless of lighting, rest, amount of close work, or vitamins taken. Most astigmatism remains fairly constant throughout life (in the absence of keratoconus).

Educational implications for refractive errors focus primarily on identification through early and continual, adequate vision screening, referral, and follow-up. Most refractive errors found in school children can be corrected with lenses. The major exception is the child with high myopia, who may be unable to be fully corrected. Magnification, higher levels of illumination, and/or telescopic aids may be indicated. Certainly, a low vision evaluation should be pursued for these children.

In the case of degenerative myopia, the associated problems should be addressed (e.g., central vision loss). Educational adjustments may need constant re-evaluation as the ocular condition progresses.

# Syndromes

A group of symptoms that occur together; may affect the whole body or any of its parts. The following selected syndromes affect the eye.

Syndrome	General Body Characteristics	Ocular Involvement
<b>Batten-Mayou</b>	Cerebral degeneration; amaurotic familial idiocy; appears in childhood; early death.	
<b>Bourneville's Disease (also called Tuberous Sclerosis)</b>	Inherited as autosomal dominant; adenoma sebaceum (large "blackheads"); central nervous system tumors; renal tumors; multiple lung cysts; seizures; mental retardation; appears at birth or within the first few years; death in teens.	Retinal tumors.
<b>Coat's Disease</b>	--	Chronic, progressive, inflammatory condition of the retina; exudations cause retinal detachment; iritis; glaucoma; cataracts; occurs mostly in males.
<b>Down's Syndrome</b>	Small stature; flattened/round mongoloid faces; saddle nose; thick lower lip; large tongue; soft, seborrheic skin; smooth hair; obesity; small genitalia; short fingers; simian fold; congenital heart anomalies; mental retardation; psychic disturbances.	Hyperplasia of iris; narrow palpebral fissures; high myopia; strabismus; cataracts; gray spots on the iris.
<b>Edward's (Trisomy 18)</b>	Mental and physical retardation; congenital heart defects; renal abnormalities	Corneal and lenticular opacities; unilateral ptosis; optic atrophy.
<b>Galactosemia</b>	Allergy to milk; autosomal recessive inheritance pattern. If not identified and treated (withdrawal of milk and milk products), can cause enlarged liver and mental retardation.	If untreated, cataracts develop.
<b>Grave's (Hyperthyroidism)</b>	An endocrine problem; pretibial myxedema (clubbing of the fingers)	Lid retraction; proptosis; extraocular muscle involvement; corneal involvement; optic nerve involvement; most common in women.
<b>Hurler's (Type I)</b>	Autosomal recessive; gargoylism; thick tongue; puffy cheeks; umbilical hernia; flat nose-bridge; dwarfism; mental retardation.	corneal clouding; buphthalmos; megalocornea; esotropia; slight ptosis; pigmentary retinopathy; optic atrophy.
<b>Laurence-Moon-Biedl</b>	Autosomal recessive; obesity; mental retardation; polydactyly; hypogenitalism.	Retinitis pigmentosa.
<b>Lowe's</b>	X-linked; cerebral defects, mental retardation; dwarfism; renal dysfunction; high early mortality rate.	congenital cataracts; infantile glaucoma; nystagmus; occur only in males.
<b>Marchesani's</b>	Autosomal recessive; multiple skeletal abnormalities; short and stocky with well developed muscles; hands and feet spade-shaped; childhood X-rays show delayed carpal and tarsal ossification.	Spherophakia; ectopia lentis, which leads to lenticular myopia; iridonesis; glaucoma (which resists treatment); poor visual prognosis.

<b>Syndrome</b>	<b>General Body Characteristics</b>	<b>Ocular Involvement</b>
<b>Marfan's</b>	Autosomal dominant; arachnodactyly (increased length of long bones, especially in fingers and toes); scanty subcutaneous fat; relaxed ligaments; congenital heart disease; spine/joint deformities; high infant mortality rate.	Dislocated lens (usually superiorly and nasally); severe refractive errors; megalocornea; cataract; uveal colobomas; secondary glaucoma.
<b>Patau's (Trisomy 13)</b>	Cerebral defects; cleft palate; heart lesions; polydactyly; hemangiomas; death by 6 months.	Anophthalmos; microphthalmos; retinal dysplasia; optic atrophy; coloboma of uvea; cataracts.
<b>Refsum's</b>	Spinocerebellar ataxia; deafness; polyneuritis.	Retinal degeneration.
<b>Rubella</b>	Maternally induced infection of fetus; heart abnormalities; hearing defects; sometimes mental retardation.	Bilateral cataracts; uveal colobomas; searching nystagmus; microphthalmus; strabismus; retinopathy; glaucoma.
<b>Spielmeyer-Vogt</b>	Autosomal recessive; central nervous system disorders; mental deterioration; spasticity; epilepsy and seizures; appears in childhood; death in teens.	Cerebromacular degeneration, involving the outer layers of the retina; pallor of the optic disk.
<b>Bielschowsky's</b>	(similar to Spielmeyer-Vogt)	Cerebromacular degeneration, involving all layers of the retina.
<b>Stevens-Johnson</b>	Hypersensitivity to drugs or food (rash develops).	Purulent conjunctivitis; occlusion of lacrimal gland ducts (which produces a "dry eye;" corneal ulcers and panophthalmitis.
<b>Still's Disease</b>	Juvenile rheumatoid arthritis, especially in the knee joints.	Chronic uveitis; cataracts; secondary glaucoma; band-shaped keratopathy; ocular complications occur three times as often in girls.
<b>Sturge-Weber</b>	Autosomal dominant; port-wine-stain angioma on one side of the face; central nervous system disorders (including jacksonian convulsive seizures; no treatment; death by age 30.	Unilateral infantile glaucoma on the affected side; appears at birth; choroidal hemangioma.
<b>Tay-Sachs</b>	Autosomal recessive; mental and physical deterioration in Jewish infants, first 2-3 years of life; death shortly after.	Cerebromacular degeneration; degeneration of inner layer of the retina; retinal pigmentary changes; optic atrophy; characterized by "cherry red" spot in macula.
<b>Turner's (monosomy)</b>	Affects females; retarded growth; rudimentary ovaries and female genitalia; amenorrhea.	pterygium colli; epicanthus; ptosis; color blindness
<b>Usher's</b>	Congenital hearing loss to some degree, but usually deteriorates in teen years.	Retinitis pigmentosa.
<b>Wilson's</b>	Recessive inheritance pattern; neurological symptoms (chorea, spasticity, dysarthria, dysphagia); cirrhosis of the liver; faulty renal function; linked to defects in copper metabolism.	Pigment ring in periphery of cornea (progressive, but rarely occludes the pupil); sometimes cataracts.

# CHARGE Association (Etiology Unknown)

Percent*	
80%	<b>C</b> oloboma - ranging from isolated iris coloboma, without visual impairment, to clinical anophthalmos; retinal coloboma most common.
80%	<b>H</b> ear defect - tetralogy of Fallot, patent ductus arteriosus, double outlet right ventricle with an atrioventricular canal, ventricular septal/atrial septal defect, right-sided aortic arch.
58%	<b>A</b> tresia choanae - passageway from posterior nasal cavity into the nasopharynx closed, membranous and/or bony.
87%	<b>R</b> etarded physical growth and/or mental development (94%) (usually normal birth weight, but delayed growth during the first 6 months post-natally); CNS deficiency.
88%	<b>G</b> enital hypoplasia - hypogonadism, especially in males.
88%	<b>E</b> ar anomalies and/or deafness - ranging from small ears without malformation, to cup-shaped lop ears; either sensorineural or mixed sensorineural and conductive deafness (ranging from mild to profound).

Other findings: micrognathia; cleft lip; facial palsy; feeding/ sucking problems as a result of velopharyngeal incompetence; renal abnormalities; omphalocele; tracheoesophageal fistula; rib anomalies; ptosis.

Caused by: altered morphogenesis during 2nd month of gestation.

\* Percent of children who have this characteristic as part of the CHARGE Association syndrome

---

**Description:**

---

**Treatment:**

---

**Implications:**

---

**Description:**

---

**Treatment:**

---

**Implications:**





# References

- Beck, R. & Smith, C. (1988). *Neuro-ophthalmology: A problem oriented approach*. Boston: Little, Brown, and Company
- Cassin, B. & Solomon, S. (1990). *Dictionary of eye terminology*. Gainesville, FL: Triad Publishing Company.
- Catalano, R. & Nelson, L. (1994). *Pediatric ophthalmology*. Norwalk, CT: Appleton & Lange.
- Faye, E. (1976). *Clinical low vision*. Boston: Little, Brown, and Company.
- Gittinger, J. & Asdourian, G. (1988). *Manual of clinical problems in ophthalmology*. Boston: Little, Brown, and Company
- Isenberg, S. (1989). *The eye in infancy*. Chicago: Year Book Medical Publishers, Inc.
- Newell, F. (1992). *Ophthalmology: Principles and concepts*. St. Louis: Mosby Year Book.
- Newman, N. (1992). *Neuro-ophthalmology: A practical text*. Norwalk, CT: Appleton & Lange.
- Pavan-Langston, D. (1985). *Manual of ocular diagnosis and therapy*. Boston: Little, Brown and Company
- Stein, H. & Slatt, B. (1983). *The ophthalmic assistant: Fundamentals and clinical practice*. St. Louis: Mosby Year Book
- Stein, H., Slatt, V., & Stein, R. (1992). *Ophthalmic terminology*. St. Louis: Mosby Year Book,
- Vaughan, D. & Asbury, T. (most recent edition). *General ophthalmology*. Norwalk, CT: Appleton & Lange

# Additional Resources

- Bishop, V. (1996). *Teaching visually impaired children*. Springfield, IL: Charles C. Thomas.
- Corn, A. & Koenig, A. (Eds.). (1996). *Foundations of low vision: clinical and functional perspectives*. New York: American Foundation for the Blind.
- Holbrook, C. (1996). *Children with visual impairment: A parents' guide*. Bethesda, MD: Woodbine House, Inc.
- Koenig, A. & Holbrook, C. (1993). *Learning media assessments of students with visual impairments*. Austin, TX: Texas School for the Blind and Visually Impaired.
- Levack, N. (1991). *Low vision: A resource guide with adaptations for students with visual impairments*. Austin, TX: Texas School for the Blind and Visually Impaired.



This project is supported by the U.S. Department of Education Special Education Programs (OSEP). Opinions expressed here the authors and do not necessarily represent the position of the Department of Education.